SARS-CoV-2 and newborn

Prakesh Shah
Pediatrician – in – Chief
Mount Sinai Hospital
University of Toronto, Canada

Goals

- Neonatal resuscitation
- Neonatal cases of positivity/ infection – controversies and confusion
- Room-in or room-out
- Breastfeeding / expressed breast milk / alternatives
- Parental visitation / follow up
- Recent registry results

Obstetrics & Gynaecology
UNIVERSITY OF TORONTO

Neonatal Resuscitation and Postresuscitation Care of Infants Born to Mothers with Suspected or Confirmed SARS-CoV-2 Infection

Delivery room considerations for born to mothers with suspe COVID-19

Novel corona virus disease (COVID-19) in pregnancy: What clinical recommendations to follow?

Special Report

COVID-19) pandemic

Concerning COVID-19

eral Guidelines in the Management of an Obstetrical Patient on the Labor and Delivery Unit during the COVID-19 Pandemic

NICU care for infants born to mothers with suspected or proven COVID-19

Prescreen pregnant woman and partner/visitor prior to arrival at the hospital

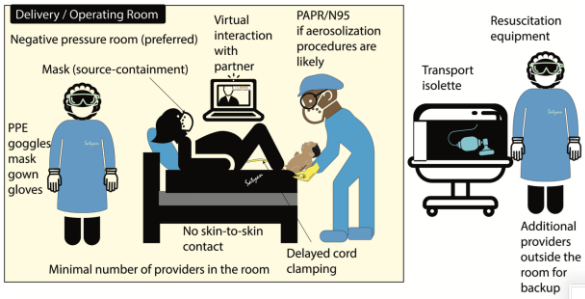

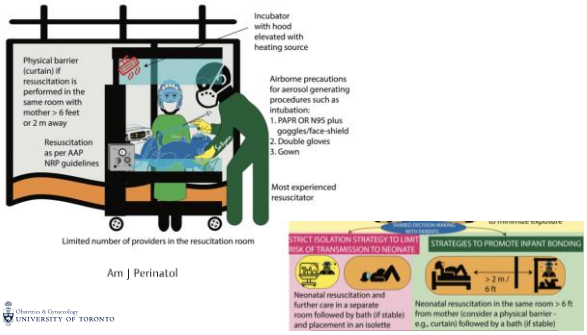

Am J Perinatol

Obstetrics & Gynecology UNIVERSITY OF TORONTO

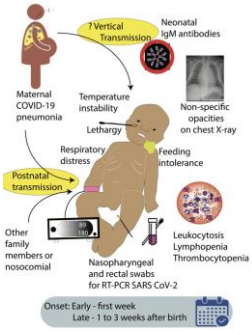

Obstetrics & Gynecology UNIVERSITY OF TORONTO

Am J Perinatol

Characteristics and controversies of neonatal cases

Early Online Release

INFECTIONS IN PREGNANCY WITH COVID-19 AND OTHER RESPIRATORY RNA VIRUS DISEASES ARE RARELY, IF EVER, TRANSMITTED TO THE FETUS: EXPERIENCES WITH CORONAVIRUSES, HPIV, hMPV RSV, AND INFLUENZA

David A. Schwartz, MD, MS Hyg; Amareen Dhaliwal, BS — ARCHIVES of Pathology & Laboratory Medicine

Neonatal Early-Onset Infection With SARS-CoV-2 in 33 Neonates Born to Mothers With COVID-19 in Wuhan, China

Obstetrics & Gynecology UNIVERSITY OF TORONTO

The SARS-CoV-2 receptor ACE2 expression of maternal-fetal interface and fetal organs by single-cell transcriptome study

in neonatal mice at post-natal day 1~3. In summary, this study revealed that the SARS-CoV-2 receptor was widely spread in specific cell types of maternal-fetal interface and fetal organs. And thus, both the vertical transmission and the placenta dysfunction/abortion caused by SARS-CoV-2 need to be further carefully investigated in clinical practice.

Obstetrics & Gynecology UNIVERSITY OF TORONTO

PLOS ONE | https://doi.org/10.1371/journal.pone.0230295 April 16, 2020

RESEARCH LETTER

Neonatal Early-Onset Infection With SARS-CoV-2 in 33 Neonates Born to Mothers With COVID-19 in Wuhan, China

Lingkong Zeng, MD
Shiwen Xia, MD
Wenhao Yuan, MD
Kai Yan, MD
Feifan Xiao, MS
Jianbo Shao, MD
Wenhao Zhou, MD

Figure. Timeline and Imaging Findings of 3 Neonates Infected With Severe Acute Respiratory Syndrome Coronavirus 2 (SARS-CoV-2)

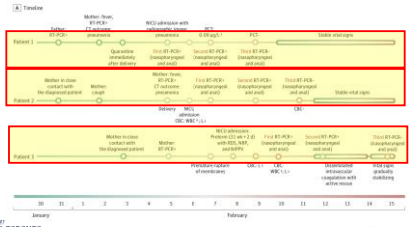

JAMA Pediatrics Published online March 26, 2020

Clinical features and obstetric and neonatal outcomes of pregnant patients with COVID-19 in Wuhan, China: a retrospective, single-centre, descriptive study

Lancet Infect Dis 2020; 20: 559-64

	Patient 1	Patient 2	Patient 3	Patient 4	Patient 5	Patient 6	Patient 7
Pregnancy outcome	Discharged	Discharged	Discharged	Discharged	Discharged	Discharged	Discharged
Neonatal outcome	Normal	Normal	Normal	Normal	Normal	Normal	Normal
Birthweight, g	3250	3350	3200	3000	3500	3300	3250
Apgar score (1 min)	8–9	8–9	8–9	8–9	8–9	8–9	8–9
Apgar score (5 min)	9–10	9–10	9–10	9–10	9–10	9–10	9–10
Admission to neonatology department	Yes	No	Yes	No	No	No	Yes
Nucleic acid test of SARS-CoV-2	Positive (36 h)	Not tested	Negative	Not tested	Not tested	Not tested	Negative
Days of follow-up	40	28	28	28	28	28	28
Neonatal complications	No	No	No	No	No	No	No

None of the women were admitted to intensive care. Normal=no respiratory symptoms or fever or neonatal complications, such as neonatal respiratory distress syndrome, feeding abnormalities, or abnormal growth or development. SARS-CoV-2=severe acute respiratory syndrome coronavirus 2.

Table 2: **Maternal and neonatal outcomes of seven patients with COVID-19**

BJOG An International Journal of Obstetrics and Gynaecology

Enrico Ferrazzi, Luigi Frigerio, Valeria Savasi, Patrizia Vergani, Federico Prefumo ... See all authors

First published:27 April 2020 | https://doi.org/10.1111/1471-0528.16278

MAIN RESEARCH ARTICLE Free Access

Vaginal delivery in SARS-CoV-2 infected pregnant women in Northern Italy: a retrospective analysis

In 10 cases breastfeeding was allowed with surgical mask. In two women who had diagnosis of COVID-19 infection in the post-partum period and breastfed without surgical mask the new-borns had positive test for COVID-19 infection at day one and three, respectively.

In another case after vaginal delivery the new-born of an infected woman had a positive test

This cases deserves additional details. The newborn from a COVID-19 mother delivered vaginally at term in good conditions, was immediately separated for a severe maternal postpartum hemorrhage. Within a few hours he developed gastrointestinal symptoms, after three days he developed respiratory symptoms and was transferred to NICU where he recovered after one day of mechanical ventilation. The first test for SARS-CoV-2 was doubtful few hours after delivery, and positive three days later.

The mother did not breastfeed and no health care provider had a confirmed diagnosis of COVID-19 infection.

Severe Acute Respiratory Syndrome Coronavirus 2 (SARS-CoV-2) Vertical Transmission in Neonates Born to Mothers With Coronavirus Disease 2019 (COVID-19) Pneumonia

OBSTETRICS & GYNECOLOGY

Xiaolin Hu, MD, Jinzhi Gao, MD, PhD, Xiaoping Luo, MD, PhD, Ling Feng, MD, PhD, Weiyang Liu, MD, Juan Chen, MD, PhD, Alexandra Benachi, MD, PhD, Daniele De Luca, MD, PhD, and Ling Chen, MD, PhD

Table 2. Clinical Characteristics of the Neonates

Characteristic	Case No. 1*	2	3	4	5	6	7
Sex	Male	Male	Female	Male	Male	Male	Male
Gestational age (wk)	40	41 2/7	38 4/7	39 5/7	38 2/7	38 2/7	37 2/7
Birth weight (g)	3,250	3,470	3,250	3,670	3,180	3,200	3,300
1-min Apgar score	8	8	8	8	7	8	8
5-min Apgar score	9	9	9	9	8	9	9
Fever	No	No	No	No	No	No	No
Transfusion of blood product	No	No	No	No	No	No	No
Weight loss (%)	0	2.9	2.5	5.4	1.9	2.5	3
Complications	No	No	No	No	No	No	No
Chest radiograph	Normal	Normal	Normal	Normal	Normal	Normal	Normal
RT-PCR for SARS-CoV-2	Positive*	Negative	Negative	Negative	Negative	Negative	Negative

Severe COVID-19 during Pregnancy and Possible Vertical Transmission

Maria Claudia Alzamora, MD[1] Tania Paredes, MD[2] David Caceres, MD[3] Camille M. Webb, MD[4,5]
Luis M. Valdez, MD[5,6] Mauricio La Rosa, MD[1,7]



Fig. 2 Timeline illustrating serologic assay results evolution in mother and neonate. Ig, immunoglobulin; RT-PCR, real-time polymerase chain reaction.

Obstetrics & Gynecology UNIVERSITY OF TORONTO

Am J Perinatol

RESEARCH LETTER

Possible Vertical Transmission of SARS-CoV-2 From an Infected Mother to Her Newborn

Lan Dong, MD
Jinhua Tian, MD
Songming He, MD
Chuchao Zhu, MD
Jian Wang, MD
Chen Liu, MD
Jing Yang, MD

Table 2. Laboratory Results for the Neonate

Time	Laboratory test	Value	Reference range
Feb 22	White blood cell count, $\times 10^9$/L	18.08	3.5-9.5
	Neutrophil count, $\times 10^9$/L	13.46	1.8-6.3
	Neutrophil ratio, %	74.5	40-75
	Lymphocyte count, $\times 10^9$/L	2.89	1.1-3.2
	Lymphocyte ratio, %	16.00	20-50
	C-reactive protein, mg/L	<5.0	0-10
	PCT, ng/mL	0.137	<0.1
	ALT, U/L	11	7-40
	AST, U/L	65	13-35
	Total bilirubin, μmol/L	44.2	0-23
	Direct bilirubin, μmol/L	7.5	0-8.0
	Creatine kinase, U/L	937	40-200
	Lactate dehydrogenase, U/L	629	120-250
	Glucose, mmol/L	2.91	3.9-6.1
	Potassium, mmol/L	4.88	3.5-5.3
	IL-6, pg/mL	28.26	≤20.0
	IL-10, pg/mL	153.80	≤5.9
	SARS-CoV-2 IgG, AU/mL	140.32	<10
	SARS-CoV-2 IgM, AU/mL	45.83	<10
Feb 24	PCR of nasopharyngeal swab	-	-
Feb 27	PCR of nasopharyngeal swab	-	-
Mar 1	PCR of nasopharyngeal swab	-	-
Mar 6	PCR of nasopharyngeal swab	-	-
Mar 7	SARS-CoV-2 IgG, AU/mL	69.94	<10
	SARS-CoV-2 IgM, AU/mL	11.75	<10
Mar 9	PCR of nasopharyngeal swab	-	-

Obstetrics & Gynecology UNIVERSITY OF TORONTO

RESEARCH LETTER

Antibodies in Infants Born to Mothers With COVID-19 Pneumonia

Hui Zeng, MD
Chun Xu, BS
Jianli Fan, MD
Yuxiang Tang, PhD
Qualin Deng, MD
Wei Zhang, MD, PhD
Xingjiao Long, MD, PhD

Table 1. Antibody and IL-6 Levels in Infant Sera Samples

		Infant*					
Clinical value	Reference range	1	2	3	4	5	6
IgM, AU/mL	<10	39.6	16.25	3.79	1.9	0.96	0.16
IgG, AU/mL	<10	125.5	113.91	75.49	73.19	51.38	7.25
IL-6, pg/mL	0.1-2.9	15.07	33.65	19.16	18.15	32.75	19.62

* Infants and mothers correspond by number between tables.

Table 2. Antibody Levels in Mother Sera Samples

		Mother*					
Clinical value	Reference range	1	2	3	4	5	6
IgM, AU/mL	<10	83.97	236.6	5.58	33.26	15.61	1.39
IgG, AU/mL	<10	136.72	117.37	120.63	103.46	70.05	8.12

* Mothers and infants correspond by number between tables.

jama.com

JAMA Published online March 26, 2020

Obstetrics & Gynecology UNIVERSITY OF TORONTO

A Case Report of Neonatal 2019 Coronavirus Disease in China

Shaoshuai Wang,[1] Lili Guo,[1] Ling Chen,[2] Weiyong Liu,[3] Yong Cao,[4] Jingyi Zhang,[1,a] and Ling Feng[1,*]

In December 2019, the coronavirus disease (COVID-19) caused by the novel severe acute respiratory syndrome coronavirus 2 (SARS-CoV-2) emerged in China and now has spread in many countries. Pregnant women are a population susceptible to COVID-19 and are more likely to have complications and even progress to severe illness. We report a case of neonatal COVID-19 in China with pharyngeal swabs testing positive by real-time reverse-transcription polymerase chain reaction assay 36 hours after birth. However, whether the case is a vertical transmission from mother to child remains to be confirmed.

Obstetrics & Gynecology UNIVERSITY OF TORONTO

Clinical Infectious Diseases

PRENATAL DIAGNOSIS

RESEARCH LETTER | Free Access

Preterm delivery in pregnant woman with critical COVID-19 pneumonia and vertical transmission

Marzieh Zamaniyan MD, Aghdas Ebadi MD, Samaneh Aghajanpoor Mir MD ... See all authors

First published:17 April 2020 | https://doi.org/10.1002/pd.5713

respectively. She was kept in the isolated NICU without any contact with her mother after birth. The infant was given powdered milk as a substitute of breast milk. Prior operation sample of vaginal secretion with Sterile cotton soap was obtained. During the cesarean section, 5ml of amniotic fluid was aspirated into a sterile syringe with a needle after uterine incision exactly before tearing of the membrane by gentle traction. Then the needle was removed and the amniotic fluid sample placed into sterile tubes containing 3ml of viral transport media (VTM). After delivery of the neonate, 5 ml of umbilical cord blood was aspirated and transferred to subsequent VTM. These samples immediately transferred to a specified virology center for COVID-19 with sterile, cold box (4). After delivery, nasal and first throat swabs of the newborn were obtained for COVID-19 RT-PCR tests, and all tests were negative except for amniotic fluid sample. However, the second neonate test was positive 24 hours later. After cesarean delivery,

新型冠状病毒感染专题·病例报告

中国首例新生儿新型冠状病毒肺炎

曾凌空[1] 陶旭炜[1] 袁文浩[1] 王劲[1] 刘欣[1] 刘智胜[2]

[1]华中科技大学同济医学院附属武汉儿童医院新生儿内科，武汉 430016；[2]华中科技大学同济医学院附属武汉儿童医院神经内科 430016

通信作者：刘智胜，Email：liuzsc@126.com

First case of neonate infected with novel coronavirus pneumonia in China

Zeng Lingkong[1], Tao Xuwei[1], Yuan Wenhao[1], WangJin[1], Liu Xin[1], Liu Zhisheng[2]

[1]Department of Neonatology, Wuhan Children's Hospital of Tongji Medical College, Huazhong University of Science & Technology, Wuhan 430016, China; [2]Deparment of Neurology, Wuhan Children's Hospital of Tongji Medical College, Huazhong University of Science & Technology, Wuhan 430016, China

Corresponding author: Liu Zhisheng, Email: liuzsc@126.com

SARS-CoV-2 infection with gastrointestinal symptoms as the first manifestation in a neonate

WANG Jin, WANG Dan, CHEN Guo-Ce, TAO Xu-Wei, ZENG Ling-Kong. Wuhan Children's Hospital/Wuhan Maternal and Child Healthcare Hospital, Tongji Medical College, Huazhong University of Science & Technology, Wuhan 430016, China (Zeng L-K, Email: freeman315@163.com)

Abstract: Since December 2019, the outbreak of severe acute respiratory syndrome coronavirus 2 (SARS-CoV-2) infection has occurred in Wuhan, Hubei province, China. The infected cases were noted mostly in adults, but rarely reported in children, especially neonates. Most children with SARS-CoV-2 infection present mainly with respiratory symptoms, but less commonly with gastrointestinal symptoms, and tend to have mild clinical symptoms. A neonate with SARS-CoV-2 infection, who had vomiting and milk refusal as the first symptom, was recently admitted to Wuhan Children's Hospital. After two weeks of treatment, the patient recovered gradually and was discharged now. Here, this case is reported to improve the understanding of SARS-CoV-2 infection in neonates. **[Chin J Contemp Pediatr, 2020, 22(3): 211-214]**

Key words: Severe acute respiratory syndrome coronavirus 2; Gastrointestinal symptom; Neonate

Report of the first cases of mother and infant infections with 2019 novel coronavirus in Xinyang City Henan Province

Li Mengda[1] XU Ming[2] Zhan Weiqiang[2] Han Tao[2] Zhang Guosheng[2] Lu Yibin[1]

[1]Department of Critical Care Medicine, Xinyang Central Hospital, Henan Province 464000, [2]Department of Infection, The Fifth People's Hospital, Xinyang City, Henan Province 464000

Corresponding author: Lu Yibin, Email: luyibin@163.com, Tel:0086-13937842780

【Abstract】 Objective To report the first case of a neonatal pneumonia with 2019-nCoV infection, and the experience of successfully diagnosis and treatment in late pregnancy woman with novel coronavirus pneumonia (critical type) in Xinyang city. **Methods** The successfully diagnosis and treatment of a woman with 38 weeks singleton pregnancy complicated with novel coronavirus pneumonia (critical type), and a case of neonatal pneumonia with 2019-nCoV infection were retrospectively analyzed. **Results** A single male was successfully delivered at 38-week gestation of his mother by cesarean section under third level protection in operation room. The delivery woman was diagnosed with 2019-nCoV infection at day 2 of delivery. Dyspnea and severe hypoxemia soon developed, and invasive mechanical ventilation was given. After active rescue and treatment, the delivery woman had been taken off line successfully and the condition was stable. Pharyngeal swab specimen of the neonate was sent for examination 3 days after birth, and was positive for novel coronavirus nucleic acid by fluorescence reverse transcript polymerase chain reaction. **Conclusion** 2019-nCoV may be transmitted vertically from mother to child.

【key words】 Pregnancy；2019 novel coronavirus；Pneumonia；Vertical transmission

DOI: 10.3760/cma.j.issn.1000-8680.2020.02.000

What is the confusion?

- Testing guidelines are "inconsistent and not evidence informed"
- Majority suggest testing at 24 hours but then discounts cases based on delayed testing
- Antibody testing lacks validity
- If we do not test – we will not know

Classification system and case definition for SARS-CoV-2 infection in pregnant women, fetuses, and neonates

Prakesh S. Shah[1,2,3]
Yenge Diambomba[1,2]
Ganesh Acharya[4,5]
Shaun K. Morris[2,6]
Ari Bitnun[7,8]

Congenital infection in live born neonate		
Clinical features of infection in newborn and mother with SARS-CoV-2 infection	Confirmed	Detection of the virus by PCR in umbilical cord blood[b] or neonatal blood collected within first 12 hours of birth or amniotic fluid collected prior to rupture of membrane[c]
	Probable	Detection of the virus by PCR in nasopharyngeal swab at birth (collected after cleaning baby) AND placental swab from fetal side of placenta in a neonate born via cesarean section before rupture of membrane or placental tissue
	Possible[e]	No detection of the virus by PCR in nasopharyngeal swab at birth (collected after cleaning baby) BUT presence of anti-SARS-CoV-2 IgM antibodies in umbilical cord blood or neonatal blood collected within first 12 hours of birth or placental tissue
	Unlikely	No detection of the virus by PCR in nasopharyngeal swab at birth (collected after cleaning baby) or umbilical cord blood, or neonatal blood collected within first 12 hours of birth or amniotic fluid AND antibody testing not done
	Not infected	No detection of the virus by PCR in nasopharyngeal swab at birth (collected after cleaning baby) or umbilical cord blood, or neonatal blood collected within first 12 hours of birth or amniotic fluid AND no anti-SARS-CoV-2 IgM in umbilical cord blood or neonatal blood collected within first 12 hours of birth

https://doi.org/10.1111/aogs.13870
AOGS

Skin-to-skin

- The virus is known to transmit with direct contact
- Discussion would need to happen with mothers prior to birth as to preference
- Immediate skin-to-skin is important for many parents
- Advised to not continue especially if mother is having cough/sneezing

Room-in or Room-out?

- Separation: Spain, USA (CDC), USA (AAP), China, Saudi Arabia, Singapore, South Korea
- Co-location: South Africa, Sweden, UK, USA (AAP), Canada, Italy
- Case by case: Switzerland

What do we offer?

Suggest mother and baby not be separated

Precautions:

- Mask
- Hand and breast hygiene
- Keep baby 6 feet away in-between feeds
- Watch for signs and symptoms of infection

Separation

If mother is unwell – needs to be admitted to medicine ward or ICU

If chosen by mother – separate, non-contact alternate care provider in hospital and home

EBM after precautions / formula

Obstetrics & Gynaecology
UNIVERSITY OF TORONTO

Is virus or antibody present in breastmilk?

- So far samples have been negative
- No one has reported presence of antibody in breast milk yet – active area of research

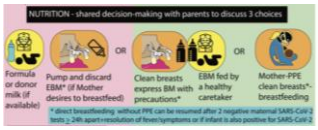

Obstetrics & Gynaecology
UNIVERSITY OF TORONTO

Breastfeeding / EBM / Alternatives

Obstetrics & Gynaecology
UNIVERSITY OF TORONTO

Management in NICU

Contact droplet precautions

AGMP – airborne precautions

Endotracheal intubation, including during cardio-pulmonary resuscitation
Cardio-pulmonary resuscitation during airway management
Open airway suctioning of intubated patients
Bronchoscopy (diagnostic or therapeutic)
Autopsy
Sputum induction (diagnostic or therapeutic)
Non-invasive positive pressure ventilation for acute respiratory failure (CPAP, BiPAP3-5)*
High flow oxygen therapy (includes heated high flow)

Adapted from Public Health Ontario. Updated IPAC measures for COVID-19, April 6th, 2020

Visitation

Positive parents – not allowed in NICU

NICU visitation:

- Only one parent allowed in a given day – door screening
- No restriction on timing
- Facilitate contact by the use of electronic medium

Discharge

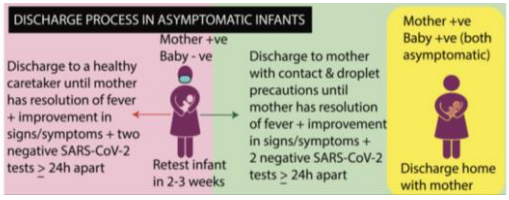

Follow up

Negative or non-suspect – community follow up

Positive mother (irrespective of baby status)

- Follow up recommended at 48-72 hours if going home (face to face)
- Hospitals encouraged to organize follow up
- Isolation till clearance by public health

What are we doing to get some answers?

Registry	Website	Patient recruitment from
PRIORITY	https://priority.ucsf.edu/	USA only
COVI-Preg	https://www.covi-preg.ch	International
PAN COVID	https://pan-covid.org	International
MFMU	https://mfmunetwork.bsc.gwu.edu/PublicBSC/MFMU/MFMUPublic/research-projects/	USA MFMU sites only
CHOPAN	https://www.covid19chopan.health	Australia, New Zealand & Pacific region
UKOSS	https://www.npeu.ox.ac.uk/ukoss/current-surveillance/covid-19-in-pregnancy	UK only
ROI COVID-19	https://www.ucc.ie/en/npec/roicovid-19study/	Ireland only
NethOSS	https://www.nvog.nl/actueel/registratie-van-covid-19-positieve-zwangeren-in-nethoss/	Netherlands only
CAN COVID-Preg	https://ridprogram.med.ubc.ca/cancovid-preg/	Canada only

US – SONPM registry - data so far



Gestational Age at Birth
38 wks (Median) Range: 33-42
Birth Weight
3273 gms (Mean) Range: 2,300 to 4638
Duration of Hospital Stay
3.9 days (Mean) Range: 1-16
Final Disposition
All 35 babies were discharged home

SONPM COVID-19 Resources:
https://collaborate.aap.org/SONPM/Pages/Perinatal%20COVID-19.aspx

Obstetrics & Gynecology
UNIVERSITY OF TORONTO

US – SONPM registry - data so far

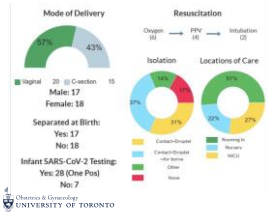

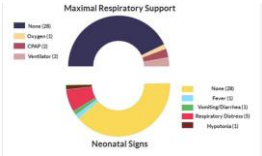

Obstetrics & Gynecology
UNIVERSITY OF TORONTO

Acknowledgements

Yenge Diambomba
Ashraf Kharrat
Wendy Whittle
Jon Barrett
Jennie Johnstone
Michelle Science
Mount Sinai Hospital – Sinai Health System

Obstetrics & Gynecology
UNIVERSITY OF TORONTO

Perinatal aspects on the covid-19 pandemic: a practical resource for perinatal–neonatal specialists

Francis Mimouni[1,2] · Satyan Lakshminrusimha[3] · Stephen A. Pearlman[4,5] · Tonse Raju[6] · Patrick G. Gallagher[7] · Joseph Mandlovic[8,9]

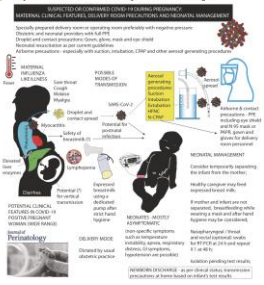

Obstetrics & Gynaecology
UNIVERSITY OF TORONTO

Journal of Perinatology (2020) 40:820–826