



Endometrial pathology

Thierry VAN DEN BOSCH, MD, PhD

Conflicts of interest: none

Endometrial pathology

1. Diagnosis

2. Staging



ULTRASOUND !

1- Diagnosis



Received: 3 September 2021 | Revised: 17 December 2021 | Accepted: 12 January 2022
 DOI: 10.1002/igs.14097

CLINICAL ARTICLE
 Gynecology

Risk assessment for endometrial cancer in women with abnormal vaginal bleeding: Results from the prospective IETA-1 cohort study

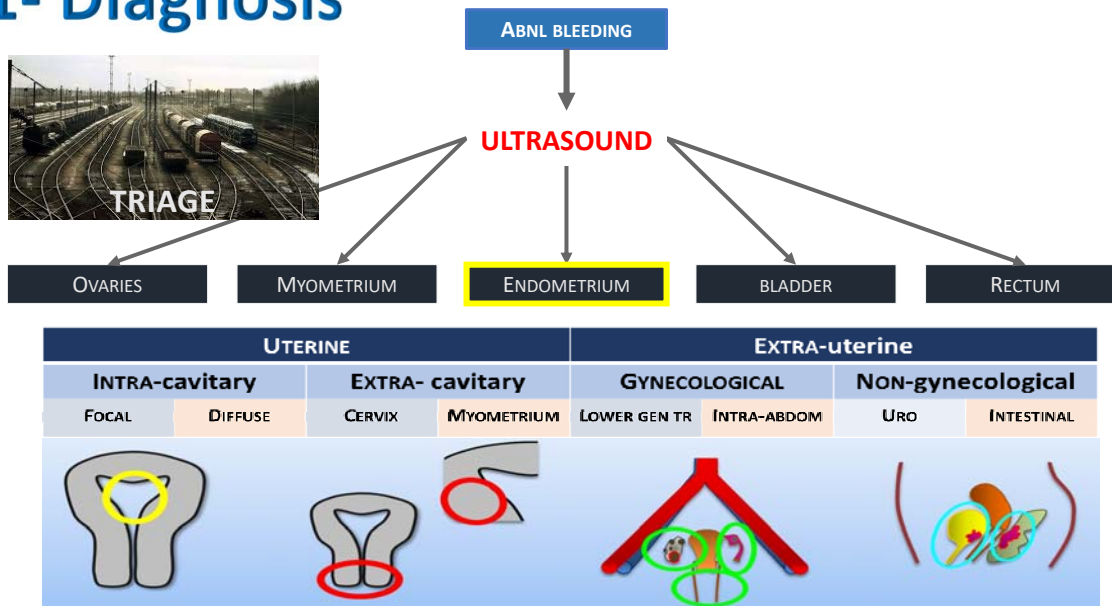
Jan Yvan Verbakel^{1,2} | Ruben Heremans^{3,4} | Laure Wynants^{3,5} | Elisabeth Epstein^{6,7} | Bavo De Cock² | Maria Angela Pascual⁸ | Francesco Paolo Giuseppe Leone⁹ | Povilas Sladkevicius¹⁰ | Juan Luis Alcazar¹¹ | Catherine Van Pachterbeke¹² | Ligita Jokubkiene¹⁰ | Robert Fruscio¹³ | Tom Bourne^{3,14} | Ben Van Calster^{3,15} | Dirk Timmerman^{3,4} | Thierry Van den Bosch^{3,4} | —for the IETA consortium



Results: Of 2417 women, 155 (6%) had endometrial malignancy or endometrial intraepithelial neoplasia. In women with endometrial cancer median age was 67 years (interquartile range [IQR] 56–75 years), median parity was 2 (IQR 0–10), and median BMI was 28 (IQR 25–32). Age, BMI, and parity produced an AUC of 0.82. Other variables marginally affected the AUC, adding endometrial thickness substantially increased the AUC in postmenopausal women.

Conclusion: Age, parity, and BMI help in the assessment of endometrial cancer risk in women with abnormal uterine bleeding. Other patient information adds little, whereas sonographic endometrial thickness substantially improves assessment.

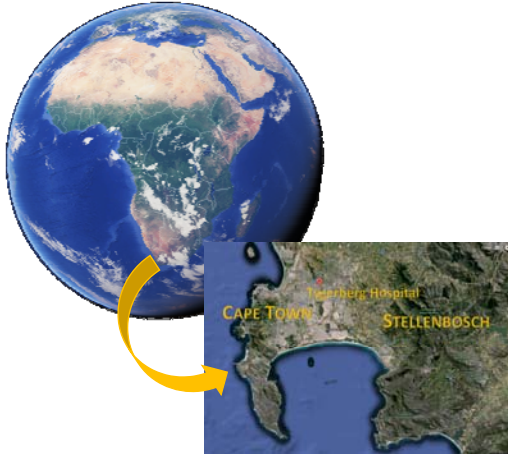1- Diagnosis



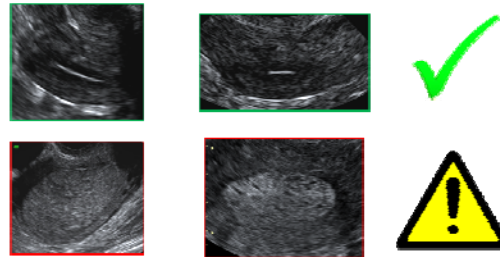
Combining Vaginal Ultrasonography and Office Endometrial Sampling in the Diagnosis of Endometrial Disease in Postmenopausal Women

T. VAN DEN BOSCH, MD, A. VANDENDAEL, MD, D. VAN SCHOU BROECK, MD,
P. A. B. WRANZ, MD, AND C. J. LOMBARD, PhD

Obstet Gynecol 1995;85:349-52

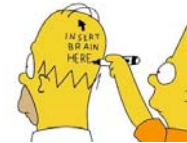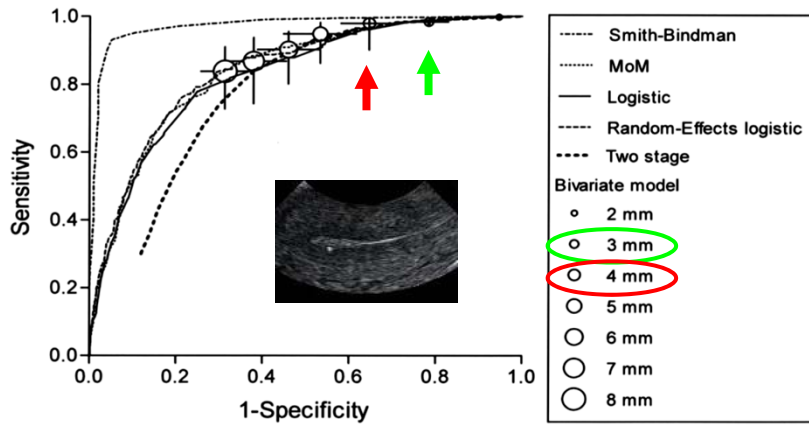


Endometrial thickness !



Meta-analysis

Endometrial thickness



Endometrial Thickness Measurement for Detecting Endometrial Cancer in Women With Postmenopausal Bleeding: A Systematic Review and Meta-Analysis

Timmermans, Anne MD; Opmeer, Brent C. PhD; Khan, Khalid S. MD, PhD; Bachmann, Lucas M. PhD; Epstein, Elisabeth MD, PhD; Clark, T. Justin MD, PhD; Gupta, Janesh K. MD, PhD; Bakour, Shagaf H. MD, PhD; van den Bosch, Thierry MD, PhD; van Doorn, Helena C. MD, PhD; Cameron, Sharon T. MD; Giusa, M. Gabriella MD; Dessole, Stefano MD, PhD; Dijkhuizen, F. Paul H. L. J. MD, PhD; ter Riet, Gerben MD, PhD; Mol, Ben W. J. MD, PhD

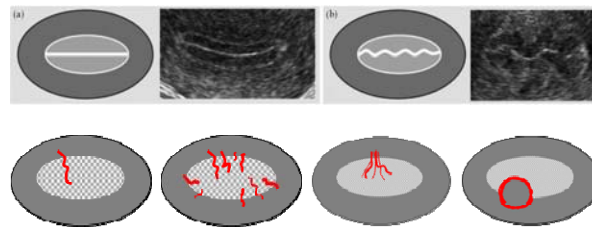
Obstetrics & Gynecology, July 2010 - Volume 116 - Issue 1 - p 160-167

Ultrasound Obstet Gynecol 2010; 35: 103–112
Published online 15 December 2009 in Wiley InterScience (www.interscience.wiley.com). DOI: 10.1002/uog.7487



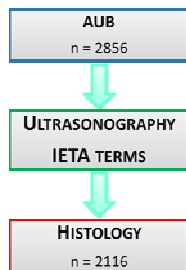
Terms, definitions and measurements to describe the sonographic features of the endometrium and intrauterine lesions: a consensus opinion from the International Endometrial Tumor Analysis (IETA) group

F. P. G. LEONE*, D. TIMMERMAN†, T. BOURNE‡, L. VALENTIN§, E. EPSTEIN¶, S. R. GOLDSTEIN***, H. MARRET††, A. K. PARSONS†††, B. GULL§§, O. ISTRE¶¶, W. SEPULVEDA***, E. FERRAZZI††† and T. VAN DEN BOSCH†



IETA-1

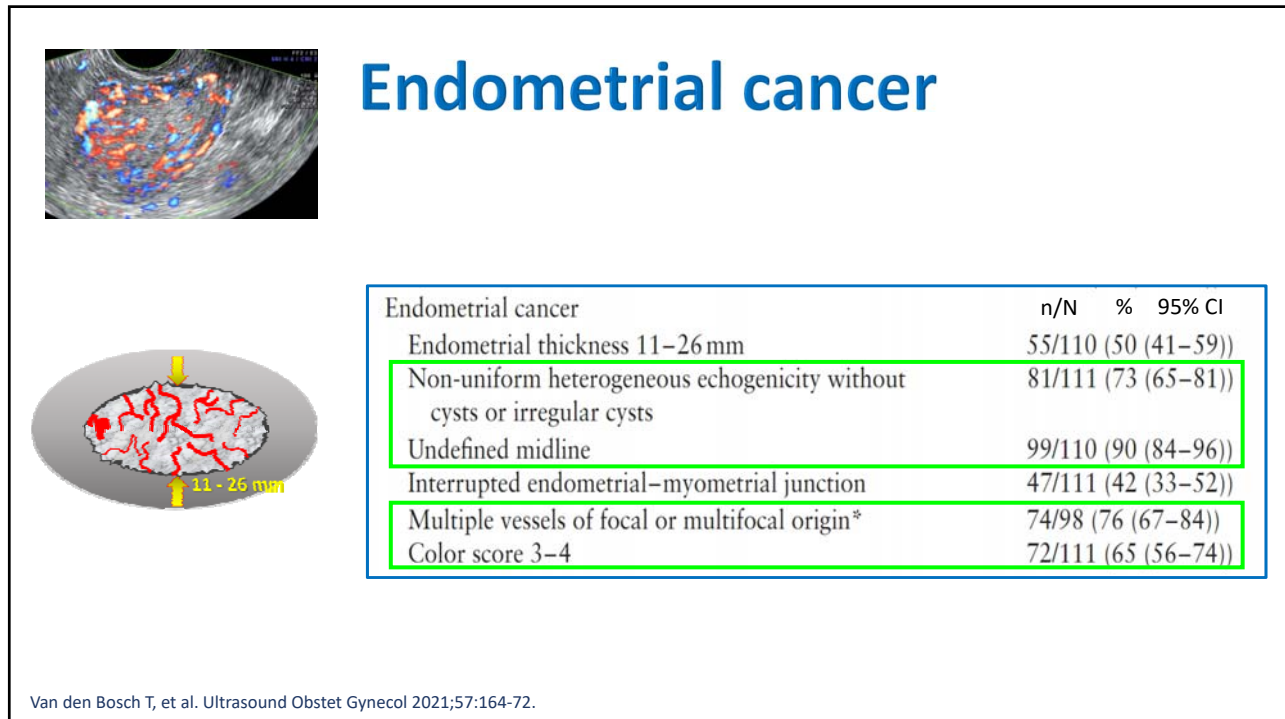
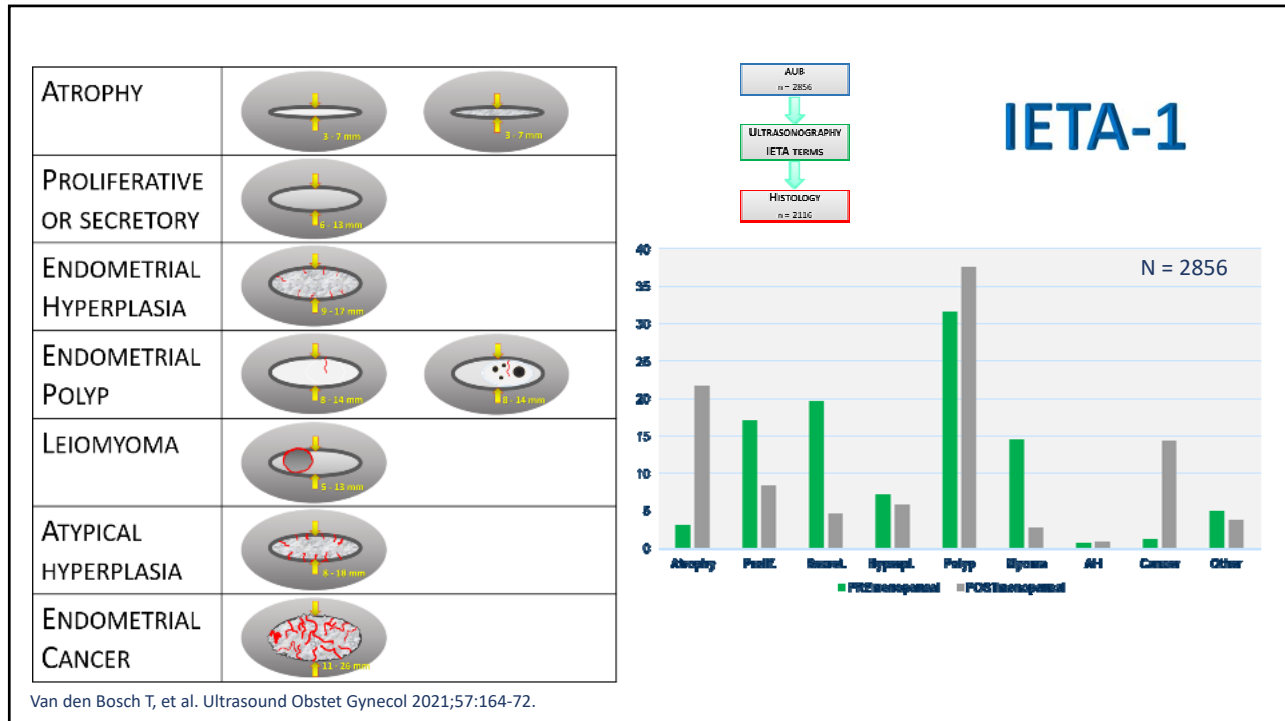
Ultrasound Obstet Gynecol 2021; 57: 164–172
Published online in Wiley Online Library (wileyonlinelibrary.com). DOI: 10.1002/uog.22109

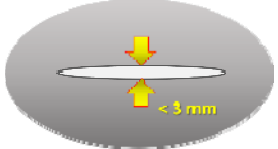


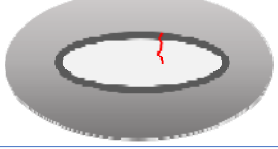



Typical ultrasound features of various endometrial pathologies described using International Endometrial Tumor Analysis (IETA) terminology in women with abnormal uterine bleeding

T. VAN DEN BOSCH^{1,2}*, J. Y. VERBAKEL³*, L. VALENTIN^{4,5}*, L. WYNANTS^{2,6}, B. DE COCK², M. A. PASCUAL⁷*, F. P. G. LEONE⁸, P. SLADKEVICIUS^{4,5}*, J. L. ALCAZAR⁹*, A. VOTINO¹⁰, R. FRUSCIO¹¹, C. LANZANI⁸, C. VAN HOLSBEKE¹², A. ROSSI¹³, L. JOKUBKIENE^{4,5}, M. KUDLA¹⁴, A. JAKAB¹⁵, E. DOMALI¹⁶, E. EPSTEIN^{17,18}, C. VAN PACHTERBEKE¹⁰, T. BOURNE^{1,2,19}, B. VAN CALSTER² and D. TIMMERMAN^{1,2}



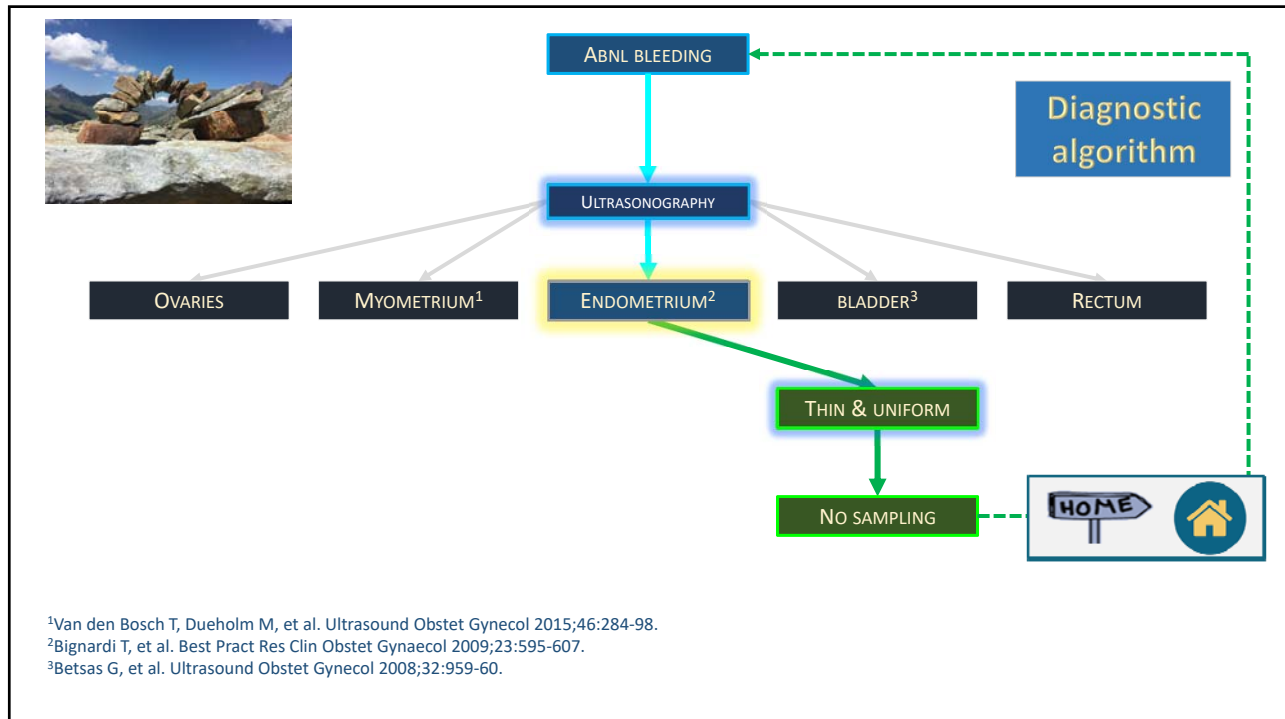


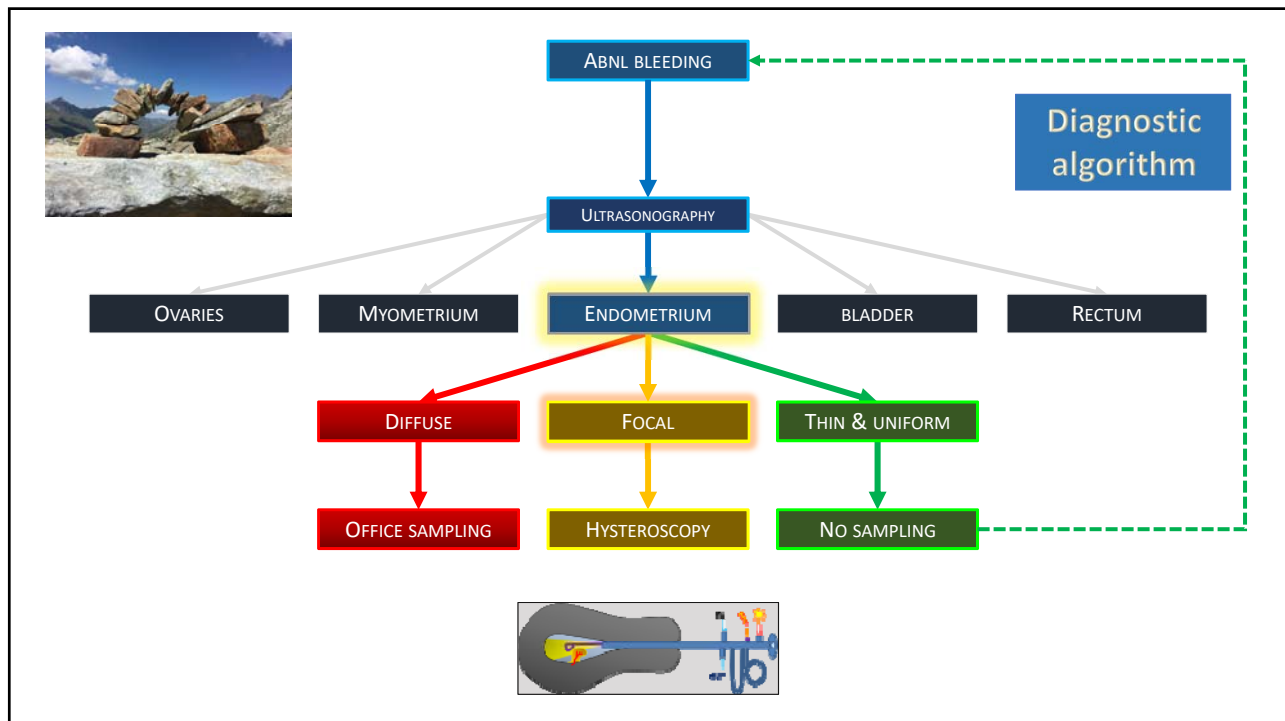
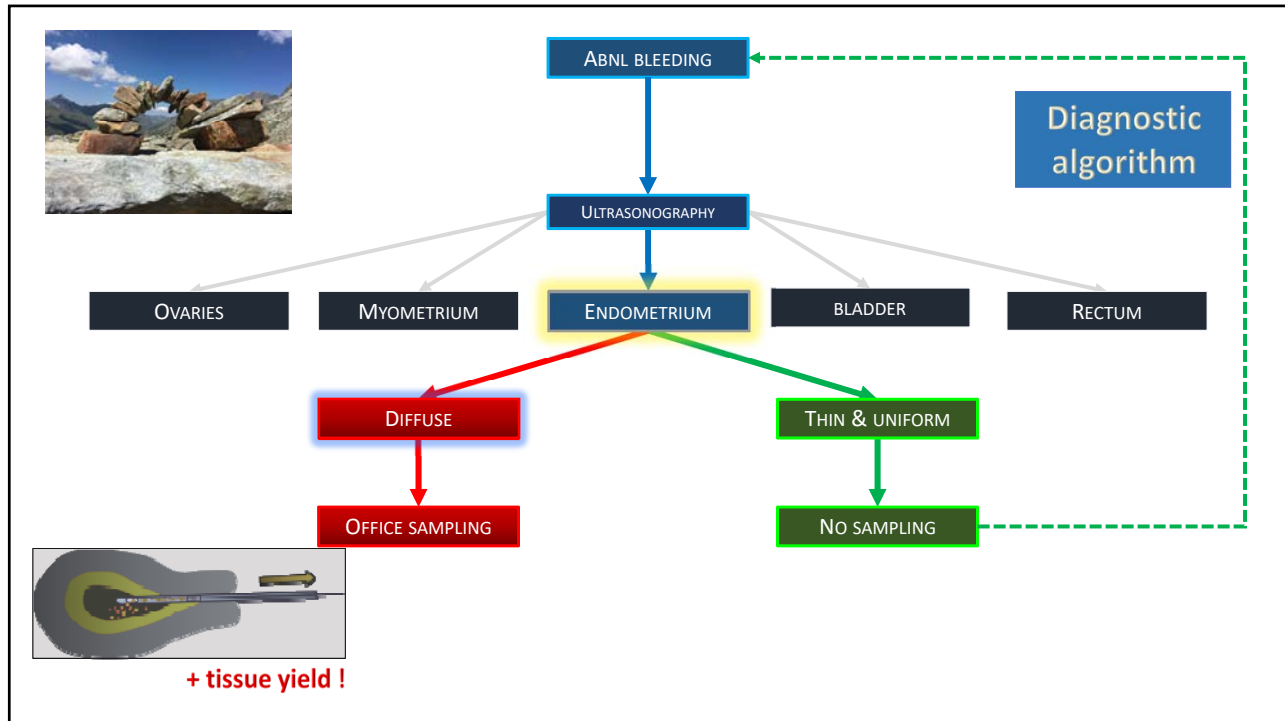
FEATURE		% (95% CI)
THIN ENDOMETRIUM < 3MM		0% (0.0 – 5.5)
3-LAYER TYPE		1.1% (0.4 – 3.1)
LINEAR MIDLINE		0.7% (0.2 – 1.3)
SINGLE VESSEL WITHOUT BRANCHING		1.5% (0.6 – 3.4)



IETA-1
N = 2856

Van den Bosch T, et al. Ultrasound Obstet Gynecol 2021;57:164-72.



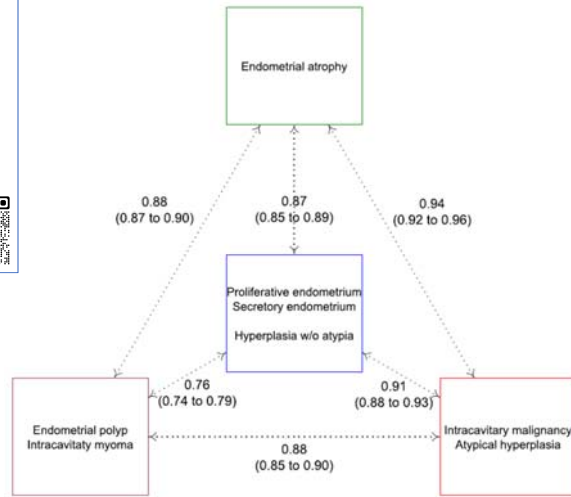
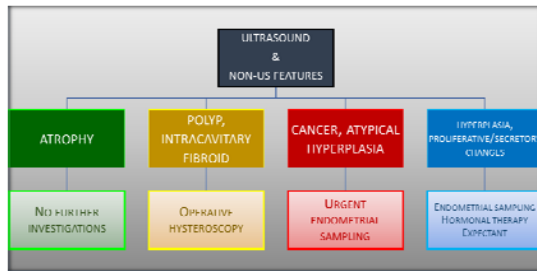


> Gynecol Obstet Invest. 2022 Feb 11. doi: 10.1159/000522524. Online ahead of print.

The risk of endometrial malignancy and other endometrial pathology in women with abnormal uterine bleeding: an ultrasound-based model development study by the IETA group

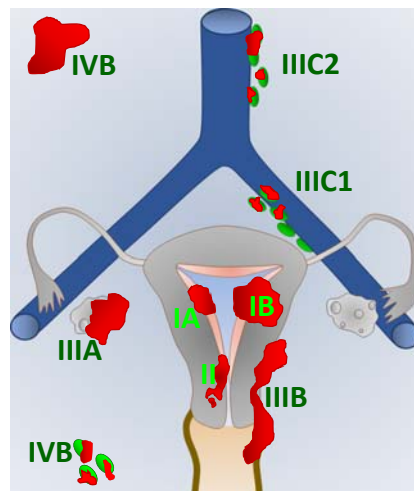
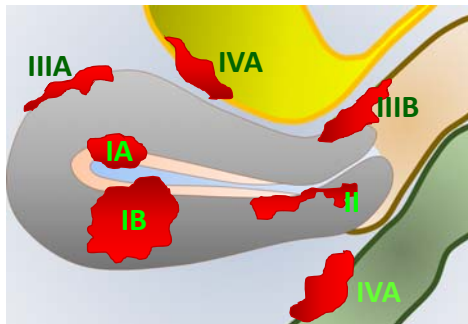
Laure Wynants, Jan Yvan Jos Verbakel, Lil Valentin, Bavo De Cock, M Angela Pascual, Francesco P G Leone, Povilas Sladkevicius, Ruben Heremans, Juan Luis Alcázar, Angelo Votino, Robert Fruscio, Elisabeth Epstein, Tom Bourne, Ben Van Calster, Dirk Timmerman, Thierry Van den Bosch

PMID: 35152217 DOI: 10.1159/000522524

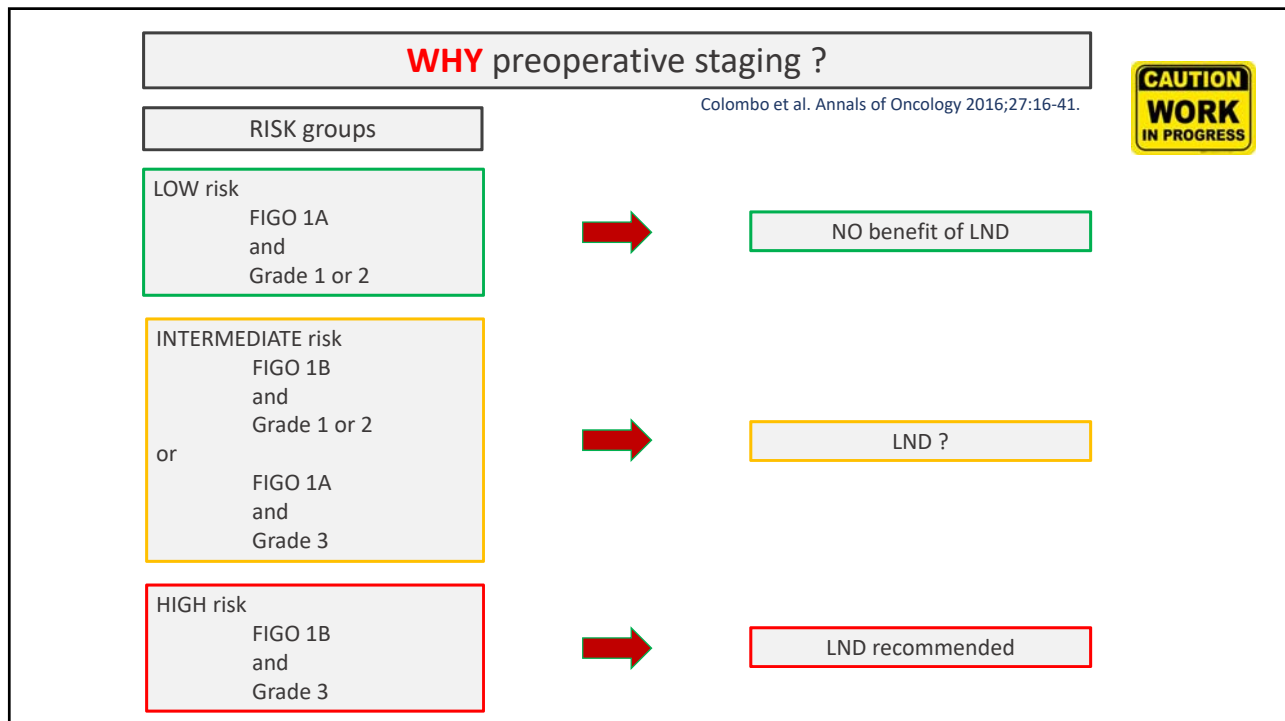
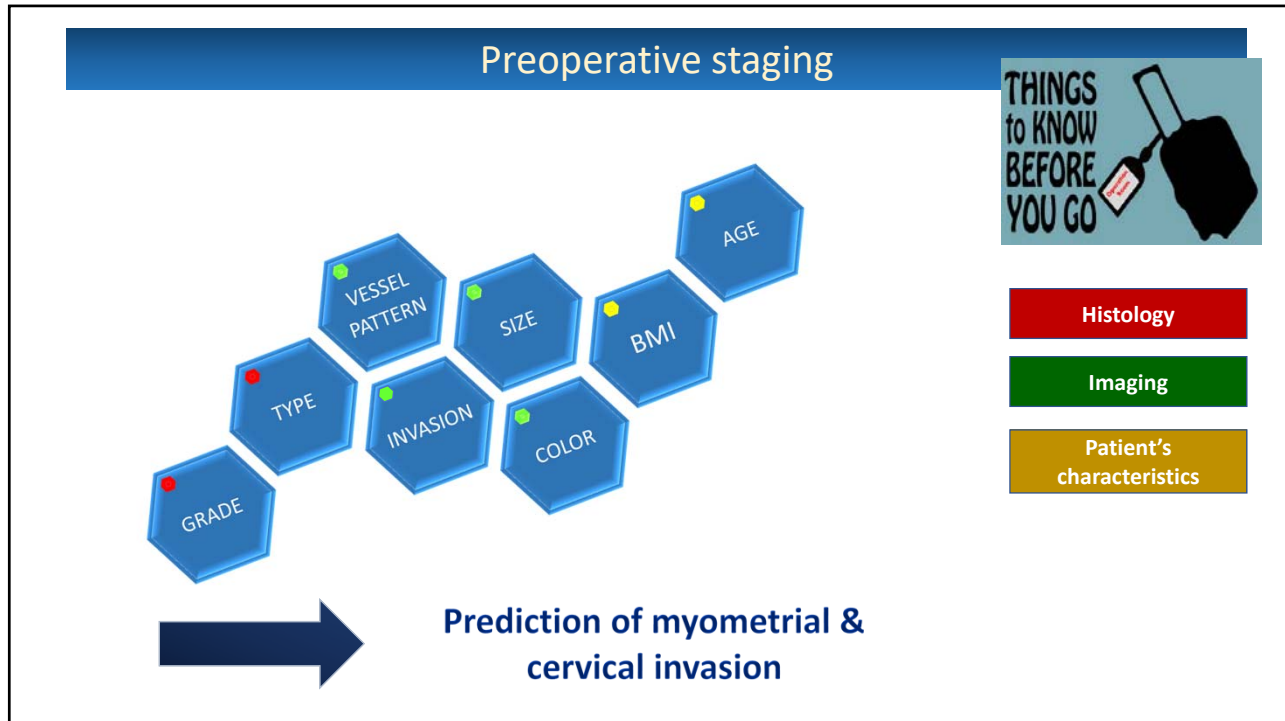


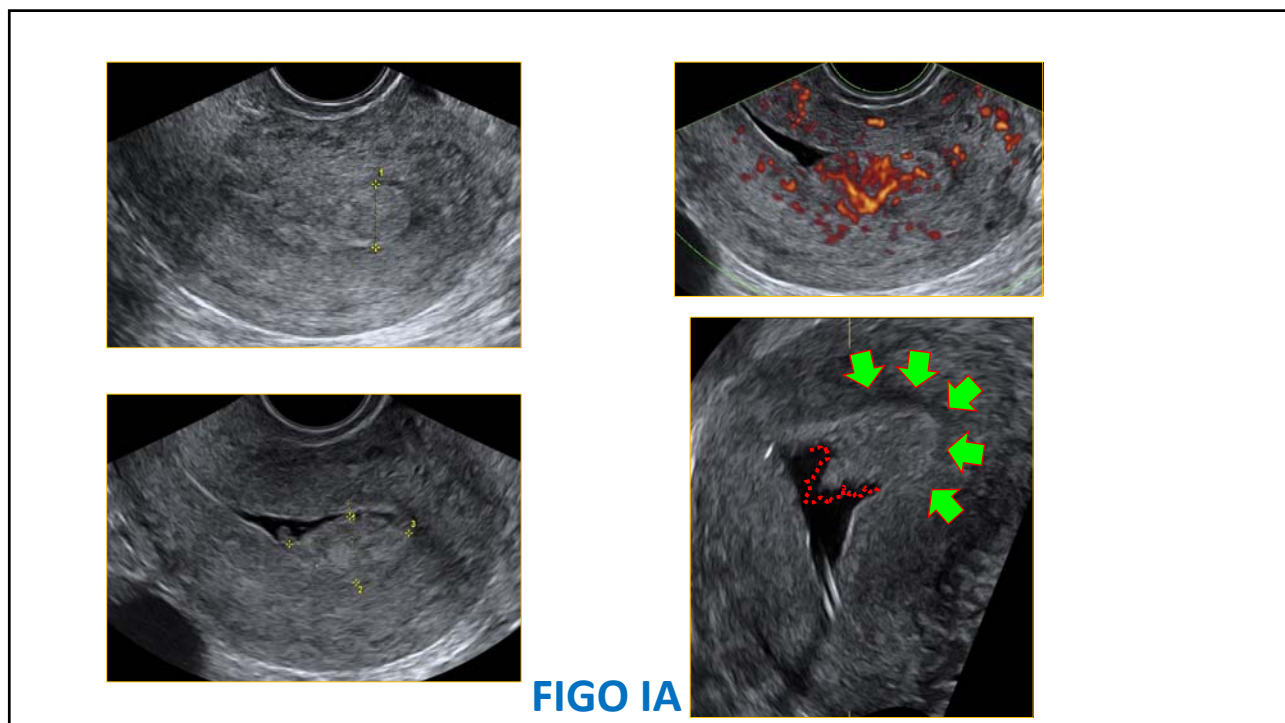
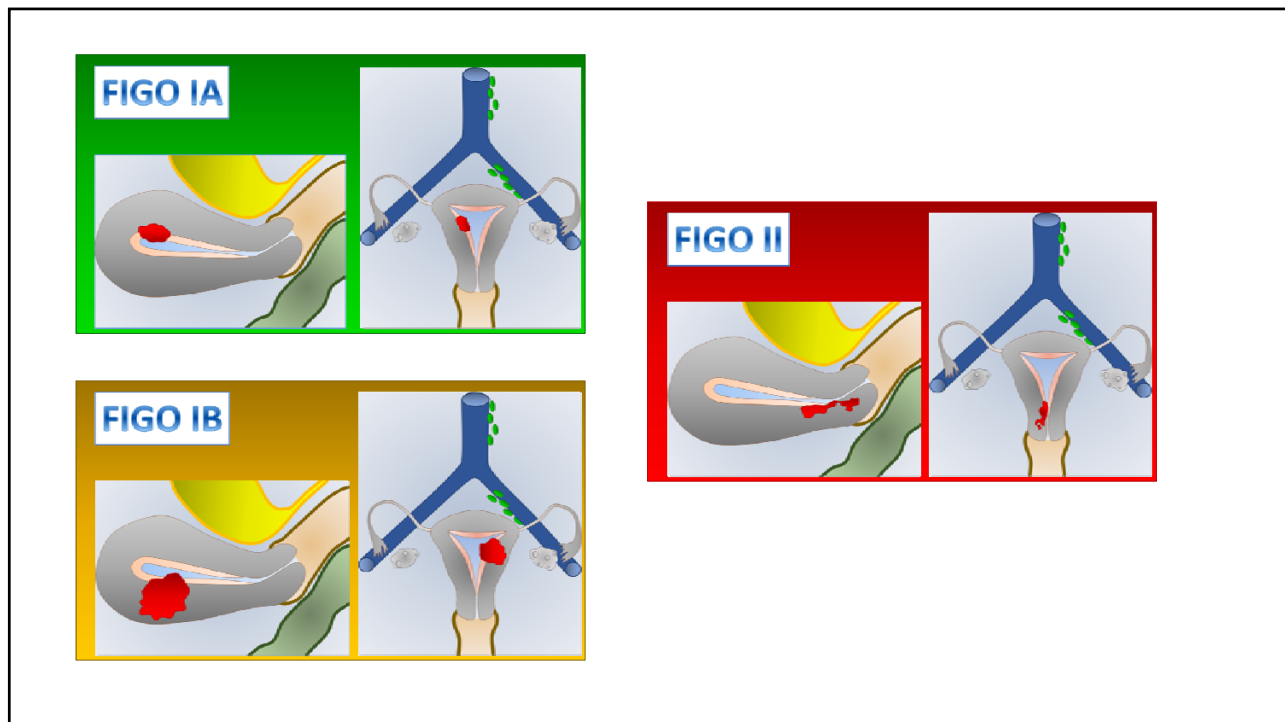
C-statistics (optimism-corrected) to distinguish between multiple outcome categories.

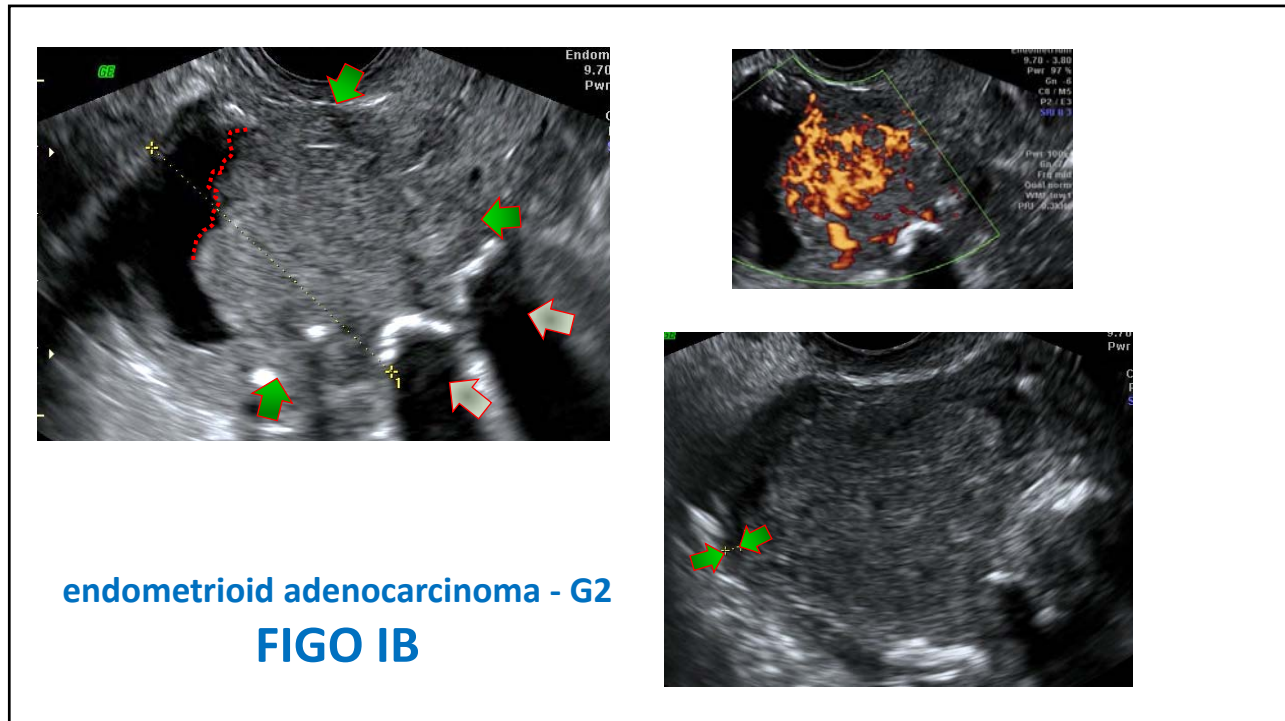
2 - Staging



Endometrial cancer: FIGO-staging







IETA-4

Ultrasound Obstet Gynecol 2018; 51: 818–828
Published online in Wiley Online Library (wileyonlinelibrary.com). DOI: 10.1002/ug.18909

Ultrasound characteristics of endometrial cancer as defined by International Endometrial Tumor Analysis (IETA) consensus nomenclature: prospective multicenter study

E. EPSTEIN¹, D. FISCHEROVA², L. VALENTIN³, A. C. TESTA⁴, D. FRANCHI⁵, P. SLADKEVICIUS⁶, F. FRÜHAUF⁷, P. G. LINDQVIST⁸, F. MASILINI⁴, R. FRUSCIO⁷, L. A. HAAK⁹, G. OPOLSKIENE⁹, M. A. PASCUAL¹⁰, J. L. ALCAZAR¹¹, V. CHIAPPA¹², S. GUERRIERO¹³, J. W. CARLSON¹⁴, C. VAN HOLSBEKE¹⁵, F. P. GIUSEPPE LEONE¹⁶, B. DE MOOR¹⁷, T. BOURNE^{18,19}, B. VAN CALSTER¹⁹, A. INSTALLE¹⁷, D. TIMMERMAN^{19,20}, J. Y. VERBAKEL^{19,21} and T. VAN DEN BOSCH²⁰

IETA

ENDOMETRIAL CANCER (preop histology)

↓

ULTRASONOGRAPHY


↓

HYSTERECTOMY
Histology
FIGO stage

N = 1538


FIGO Stage	Percentage
IA	61%
IB	21%
II	6%
IIIA	2%
IIIB	1%
IIIC1	3%
IIIC2	1%
IV	1%

Ultrasound Obstet Gynecol 2018; 51: 818–828
Published online in Wiley Online Library (wileyonlinelibrary.com). DOI: 10.1002/ug.18909



Ultrasound characteristics of endometrial cancer as defined by International Endometrial Tumor Analysis (IETA) consensus nomenclature: prospective multicenter study

E. EPSTEIN¹, D. FISCHEROVA², L. VALENTIN³, A. C. TESTA⁴, D. FRANCHI⁵, P. SLADKVICIUS⁶, F. FRÜHAUF², P. G. LINDQVIST⁶, F. MASCLINI⁴, R. FRUSCIO⁷, L. A. HAAK⁸, G. OPOLSKIENE⁹, M. A. PASCUAL¹⁰, J. L. ALCAZAR¹¹, V. CHIAPPA¹², S. GUERRIERO¹³, J. W. CARLSON¹⁴, C. VAN HOLSBEKE¹⁵, F. P. GIUSEPPE LEONE¹⁶, B. DE MOOR¹⁷, T. BOURNE^{18,19}, B. VAN CALSTER¹⁹, A. INSTALLE¹⁷, D. TIMMERMAN^{19,20}, J. Y. VERBAKEL^{19,21} and T. VAN DEN BOSCH²⁰



ENDOMETRIAL CANCER
(preop. histology)

ULTRASONOGRAPHY

HYSTERECTOMY
Histology
FIGO stage

Stage ≥ 1B (versus 1A)

Irrespective of grade


- Larger
- Irregular
- Non-uniform
(heterogeneous without cysts)
- Multiple multifocal vessel pattern
- Color score 4

High-risk tumors

(stage 1A-G3 or non endometrioid or ≥ 1B)


- Larger
- Irregular
- Non-uniform echogenicity
- Multiple multifocal vessel pattern
- Moderate or high color score

Ultrasound Obstet Gynecol 2020; 56: 443–452
Published online in Wiley Online Library (wileyonlinelibrary.com). DOI: 10.1002/ug.21950



Ultrasound-based risk model for preoperative prediction of lymph-node metastases in women with endometrial cancer: model-development study


L. S. E. ERIKSSON^{1,2}, E. EPSTEIN^{3,4}, A. C. TESTA⁵, D. FISCHEROVA⁶, L. VALENTIN⁷, P. SLADKVICIUS⁸, D. FRANCHI⁹, F. FRÜHAUF⁶, R. FRUSCIO⁹, I. A. HAAK^{10,11}, G. OPOLSKIENE¹², F. MASCLINI¹³, J. L. ALCAZAR¹⁴, C. VAN HOLSBEKE¹⁵, V. CHIAPPA¹⁶, T. BOURNE^{17,18}, P. G. LINDQVIST^{3,4}, B. VAN CALSTER¹⁸, D. TIMMERMAN^{18,19}, J. Y. VERBAKEL^{20,21}, T. VAN DEN BOSCH¹⁹ and L. WYNANTS^{18,22}



- Age
- Duration of abnormal bleeding
- Histology
- Ultrasound
 - (un)defined tumor
 - Size
 - MI
 - CSI
 - Extra-uterine spread

➔

Probability (lymph-node metastase=yes) = $\frac{1}{1+e^{-X\beta}}$



Xβ =

- 3.962
- + 0.134 × (age in years/10)
- + 0.072 × (duration of abnormal bleeding in months/3)
- + 0.607 × (1 if non-endometrioid cancer on endometrial biopsy, 0 otherwise)
- + 0.592 × (1 if ultrasound consistent with cancer but no biopsy indicating cancer, 0 otherwise)
- + 0.507 × (1 if MI ≥ 50% without CSI or extrauterine spread on ultrasound, 0 otherwise)
- + 0.512 × (1 if CSI without extrauterine spread on ultrasound, 0 otherwise)
- + 1.533 × (1 if extrauterine spread on ultrasound, 0 otherwise)
- + 0.359 × (tumor/uterine AP diameter ratio/0.25)
- + 1.046 × (1 if undefined tumor with unmeasurable endometrium, 0 otherwise).